Check for updates

ORIGINAL ARTICLE

Shoulder & Elbow

Shoulder & Elbow
2024, Vol. 0(0) 1–11
© The Author(s) 2024
Article reuse guidelines:
sagepub.com/journals-permissions
DOI: 10.1177/17585732241246718
journals.sagepub.com/home/sel
Sage

Open reduction and internal fixation versus minimally invasive plate osteosynthesis of unstable proximal humerus fractures treated with locking plate and intramedullary allograft: A retrospective study

Lyubomir Rusimov[1], Asen Baltov[1], Dian Enchev[1], Boyko Gueorguiev[2], Krasimira Prodanova[3], Mariya Hadzhinikolova[1], Vladimir Rusimov[4] and Mihail Rashkov[1]

Abstract

Background: This retrospective clinical study aims to compare the functional and radiological outcomes after open reduction and internal fixation versus minimally invasive plate osteosynthesis of unstable proximal humerus fractures treated with both locking plate and intramedullary graft.

Methods: Forty-seven patients with proximal humerus fractures were treated with either open reduction and internal fixation (25 cases) or minimally invasive plate osteosynthesis (22 cases) and evaluated retrospectively with a minimum follow-up of 12 months. Thirty-one fresh-frozen fibulae and 16 lyophilized tibia allografts were used for augmentation. Change of both neck-shaft angle and humeral head height were evaluated radiologically. Functional outcomes were assessed using Disabilities of the Arm, Shoulder and Hand Score (DASH), Absolute Constant–Murley Score (CS^{abs}), Relative Constant–Murley Score (CS^{rel}), and Individual Relative Constant–Murley Score (CS^{indiv}).

Results: Follow-up period and age for open reduction and internal fixation/minimally invasive plate osteosynthesis were $27.4 \pm 16.2/29.6 \pm 17.6$ months and $60.5 \pm 13.7/66.3 \pm 11.7$ years. CS^{abs}, CS^{rel}, and CS^{indiv} were $57.3 \pm 21.2/52.4 \pm 18.9$, $73 \pm 24.1/73.9 \pm 23.4$, and $69.6 \pm 24.8/64 \pm 25.5$ for open reduction and internal fixation/minimally invasive plate osteosynthesis, $p \geq 0.409$. DASH was $14.8 \pm 12.5/18.7 \pm 14.5$ for open reduction and internal fixation/minimally invasive plate osteosynthesis, $p = 0.324$. Decrease of neck-shaft angle and humeral head height was $7.8 \pm 9.4/8.2 \pm 15.6°$ and $0.6 \pm 5.5/1.4 \pm 2.6$ mm for open reduction and internal fixation/minimally invasive plate osteosynthesis, $p \geq 0.380$. Surgical time was $165.8 \pm 77.6/84.7 \pm 38.1$ min for open reduction and internal fixation/minimally invasive plate osteosynthesis, $p < 0.001$.

Conclusions: Locked plating with intramedullary graft augmentation of unstable proximal humerus fractures demonstrates similar functional and radiological outcomes when comparing open reduction and internal fixation with minimally invasive plate osteosynthesis. However, minimally invasive plate osteosynthesis is related to significantly shorter surgical time versus open reduction and internal fixation.

[1]Department of Trauma Surgery, University Multiprofile Hospital for Active Treatment and Emergency Medicine "N. I. Pirogov", Sofia, Bulgaria
[2]AO Research Institute Davos, Davos, Switzerland
[3]Technical University of Sofia, Sofia, Bulgaria
[4]Department of Orthopaedic Trauma and Reconstructive Surgery, Military Medical Academy, Sofia, Bulgaria

Corresponding author:
Lyubomir Rusimov, Department of Trauma Surgery, University Multiprofile Hospital for Active Treatment and Emergency Medicine"N. I. Pirogov," Boulevard Totleben 21, Sofia 1606, Bulgaria.
Email: lyubomirrusimov@gmail.com

Keywords
Proximal humerus, locking plate, augmentation, intramedullary graft, minimally invasive plate osteosynthesis, open reduction and internal fixation

Date received: 6th December 2023; accepted: 25th March 2024

Introduction

Proximal humerus fractures (PHFs) represent 53% of all shoulder girdle injuries.[1] In patients older than 65 years their incidence is ranked third, following distal radius and femoral neck fractures.[2–4] Although only 20% of these fractures are unstable and require surgical treatment,[5] the expected increase in their incidence by year 2030 will result in a higher number of corresponding surgical procedures.[3,6] Among the variety of existing fixation methods, locking plate (LP) fixation has become the gold standard for treatment of unstable PHFs.[7] However, locked plating is still associated with a high rate of complications and reoperations, mostly due to varus collapse, screw penetration in the glenohumeral joint, and avascular necrosis (AVN) of the humeral head.[8,9] Most authors suggest that these complications are related to fracture type and morphology (3- and 4-part fractures according to Neer Classification,[5] additional medial comminution,[10] osteoporosis,[11] initial varus displacement,[12,13], and indicators for ischemic changes[14]), inability to obtain anatomical or nearly anatomical reduction[15,16], and LP rigidity.[9,11]

Intramedullary grafts (IMGs) are able to recreate missing medial support by filling in osteoporotic defects and withstanding deforming rotator cuff forces and moments.[17] In a pilot study, Gardner et al.[17] enhanced the stability of LP constructs by adding intramedullary fibular allograft in 7 cases of unstable PHFs with medial calcar deficiency and/or osteoporosis, demonstrating no complications. Their promising results have leveraged the interest towards biomechanical[18–22] and clinical studies[23–36] focusing on treatment of unstable PHFs with simultaneous locked plating and intramedullary grafting. While most of these authors perform open reduction and internal fixation (ORIF), there is still a lack of reports on fixation of unstable PHFs using both LP and IMG with minimally invasive plate osteosynthesis (MIPO) technique. Furthermore, to our knowledge, there is no existing study comparing the two techniques—ORIF versus MIPO—in presence of allograft augmentation.

Therefore, the aim of this retrostpective clinical study was to compare the functional and radiological outcomes after ORIF versus MIPO of unstable PHFs treated with both LP and IMG.

Materials and methods

Ethics

This study was conducted in accordance with the principles of the Declaration of Helsinki as well as national legal and regulatory requirements. It was retrospectively registered and approval was granted by the local Ethics Committee of the authors' institution (No. EC–01/26.01.2023).

Patients

All surgical procedures were performed by 8 senior trauma surgeons. All patients were treated with simultaneous locked plating and intramedullary grafting at a level 1 trauma center from January 2015 until November 2020. The inclusion criteria considered (a) patients aged 18 years or older, (b) patients with nonpathological and unstable PHFs according to the Neer criteria[5] (displacement of more than 1 cm and/or angulation of more than 45°), (c) patients with PHFs having additional features of instability and complexity such as medial comminution, osteoporosis and/or initial varus displacement, (d) patients without history of a recent trauma to the contralateral shoulder, (e) time to surgery within 3 weeks. The exclusion criteria considered (a) patients under the age of 18 years, (b) patients with impaired shoulder function prior to the traumatic incident, (c) patients with pathological fractures, (d) open fractures, (e) fractures with a period longer than 3 weeks between injury and surgery.

Surgical technique

A standard beach chair position was used for all patients. In 25 of the cases, ORIF was performed through a deltopectoral approach. In the remaining 22 cases, MIPO technique was applied via either an anterolateral or a direct transdeltoid proximal window. A total of 31 fresh-frozen fibulae (17 for ORIF and 14 for MIPO) and 16 lyophilized tibiae (8 for ORIF and 8 for MIPO) were used as allografts, cut at a length of 6 to 8 cm and additionally shaped if their diameter could not fit in the medullary canal (Figure 1). Each graft was inserted through the lateral fracture line.

Surgical technique for ORIF

A standard deltopectoral approach with a skin incision length of approximately 12–14 cm was used, starting at the tip of the coracoid process and running laterally toward the insertion of the deltoid muscle. Careful dissection was performed so that the periosteal blood supply was preserved as much as possible.



Figure 1. Shaping of allograft's diameter.

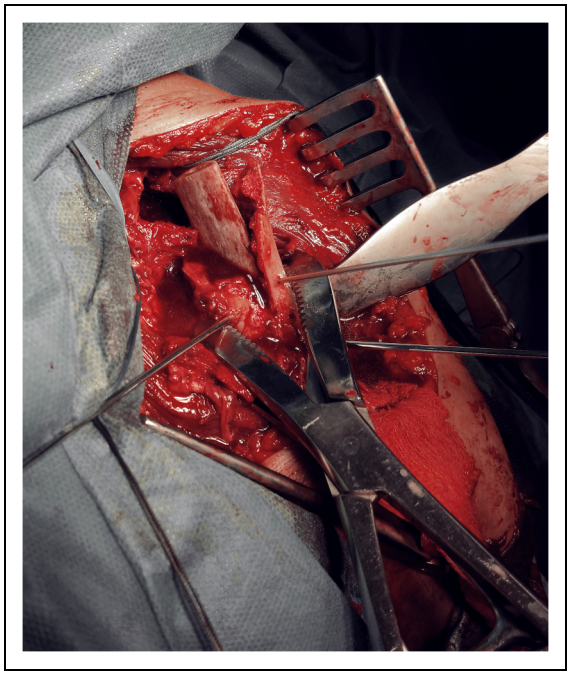

Figure 2. Insertion of IMG and temporary fixation with K-wires. IMG: intramedullary graft; K-wires: Kirschner wires.

In cases with unstable fractures plus initial varus displacement and insufficient medial cortex, the allograft was positioned intramedullary and distally to the humeral head.

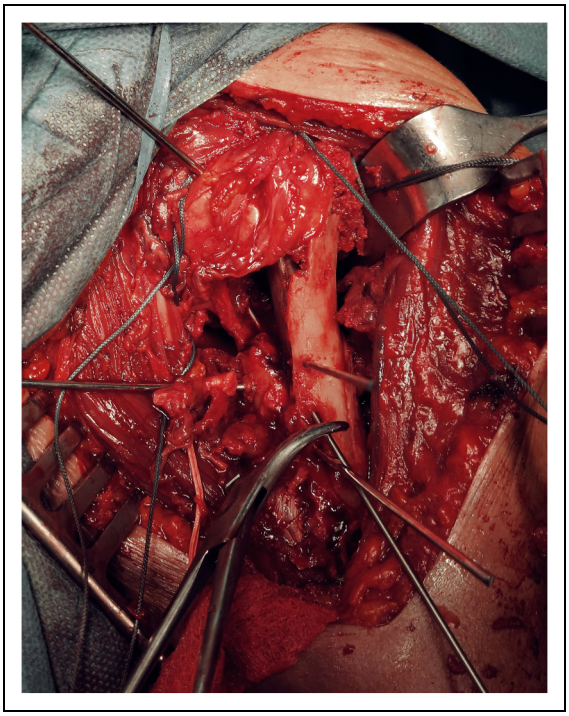

Figure 3. Reposition of the humeral head relative to the allograft height and the medial cortex.

Then it was medialized to the calcar region and elevated cranially, propping up the subchondral bone of the humeral head (Figures 2 and 3) so that the head was elevated from its varus position and aligned with the medial metaphyseal part of the bone. In these cases, the final graft position was vertical (Figure 4). In cases with unstable valgus-impacted PHFs, the graft was initially positioned in the medullary canal with its proximal part in contact with the subchondral bone of the humeral head and then pushed medially, acting as medial support and a repositioning tool for indirect reduction. In these cases, the graft was usually in vertical or sometimes in oblique position (Figure 5).

Surgical technique for MIPO

For the proximal window of the MIPO approach, a skin incision was made, starting from the anterolateral or lateral border of the acromion and extending 4–5 cm distally. For the distal window, an incision was made, starting 7 cm distal to the tip of the acromion after creation of a subdeltoid extraperiosteal tunnel by a blunt dissection. The axillary nerve was protected with the index finger during preparation of the submuscular tunnel and insertion of the plate.

The principles of graft insertion are similar to those described for ORIF. The technique for indirect reduction of valgus-displaced PHFs is particularly useful when performing MIPO. Also, when MIPO technique is applied for varus-displaced PHFs and indirect reduction is

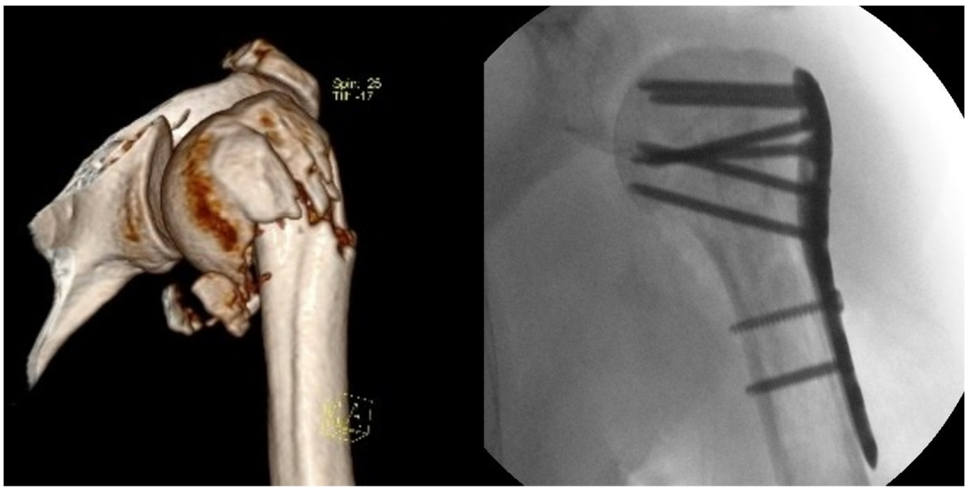

Figure 4. 3D-CT reconstruction of unstable PHF with initial varus displacement (a); intraoperative X-rays of the same fracture after LP fixation with IMG in vertical position (b). 3D: three-dimensional; CT: computed tomography; PHF: proximal humerus fracture; LP: locking plate; IMG: intramedullary graft.

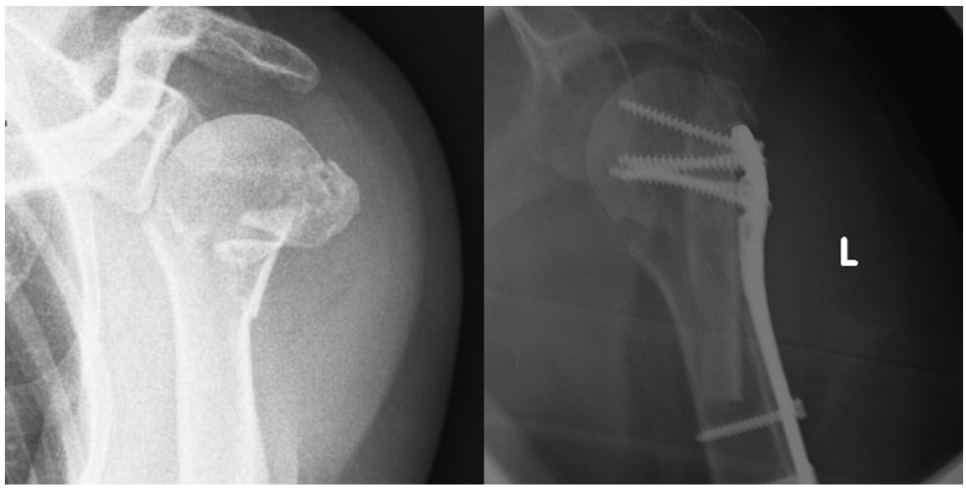

Figure 5. X-rays of a valgus-impacted PHF (a); intraoperative X-rays after MIPO showing an oblique IMG position (b). PHF: proximal humerus fracture; MIPO: minimally invasive plate osteosynthesis; IMG: intramedullary graft.

mandatory, the IMG secures a strong cortical lever arm for the instrument used to elevate the head (e.g., blunt periosteal elevator).

At least 1 plate screw should pass through the graft, regardless of which one of the two techniques is applied.

Functional outcome assessment

Functional outcomes were assessed at the final follow-up using Disabilities of the Arm, Shoulder and Hand Score (DASH) and Absolute Constant–Murley Score (CS^{abs}) with its derivatives—Relative Constant–Murley Score (CS^{rel}) calculated by using reference values of the respective age and gender group described by Constant and Murley, and Individual Relative Constant–Murley Score (CS^{indiv}), calculated as the percentage of the CS^{abs} with regard to the contralateral shoulder of the patient.[37]

Radiological evaluation

Preoperative radiographs of the shoulder in anteroposterior and Y-lateral views were obtained for all patients. For 24 of

Table 1. Categories, parameters, surgical techniques, and *p*-values from statistical comparisons.

Categories	Parameters	ORIF	MIPO	*p*-value
Patient characteristics				
	Number of patients	25	22	–
	Follow-up duration (months)	27.4 ± 16.2	29.6 ± 17.6	0.657
	Age at surgery (years)	60.5 ± 13.7	66.3 ± 11.7	0.128
	Female patients	18 (72%)	19 (86%)	0.297
	Patients < 65 years	13 (52%)	9 (41%)	0.561
	Patients ≥ 65 years	12 (48%)	13 (59%)	0.561
	Mechanism of injury			
	Falling from a standing height	13 (52%)	16 (73%)	0.386
	Falling from high altitude	4 (16%)	3 (14%)	1.000
	Road traffic accidents	3 (12%)	0 (0%)	0.236
	Other patients	5 (20%)	3 (14%)	0.705
	DTI			
	DTI < 1.4	14 (56%)	15 (68%)	0.548
	DTI ≥ 1.4	11 (44%)	7 (32%)	0.548
Fracture characteristics	Neer classification			
	2-part fracture	1 (4%)	1 (5%)	1.000
	3-part fracture	6 (24%)	8 (36%)	0.327
	4-part fracture	14 (56%)	11 (50%)	0.773
	2-part fracture with dislocation	1 (4%)	0 (0%)	1.000
	3-part fracture with dislocation	1 (4%)	1 (5%)	1.000
	4-part fracture with dislocation	2 (8%)	1 (5%)	1.000
	Calcar status			
	Comminuted	20 (80%)	16 (73%)	0.732
	Noncomminuted	5 (20%)	6 (27%)	0.732
	Initial varus displacement	14 (56%)	13 (59%)	1.000
	Hertel's criteria			
	Calcar segment < 8 mm	18 (72%)	11 (50%)	0.144
	Medial hinge disruption	21 (84%)	21 (95%)	0.352
	Anatomic neck fracture	20 (80%)	16 (73%)	0.732
Surgical technique	Allograft			
	Fresh-frozen fibula	17 (68%)	14 (64%)	0.768

(continued)

Table 1. Continued

Categories	Parameters	ORIF	MIPO	*p*-value
	Lyophilized tibia	8 (32%)	8 (36%)	0.768
	Quality of fracture reduction			
	Anatomical	12 (48%)	3 (14%)	0.014
	Acceptable	8 (32%)	10 (45%)	0.382
	Malreduction	5 (20%)	9 (41%)	0.200

ORIF: open reduction and internal fixation; MIPO: minimally invasive plate osteosynthesis; DTI: deltoid tuberosity index.

them, computed tomography (CT) was additionally performed.

Radiological evaluation considered the change of (a) neck-shaft angle (NSA) and (b) humeral head height (HHH), both registered between the intraoperative and final follow-up X-rays, and measured according to Agudelo et al. and Gardner et al., respectively.[38,39] A decrease of more than 10° for NSA and/or more than 5 mm for HHH were considered as criteria for loss of fracture reduction.[38,39] Evaluation of the local bone quality was performed by using the deltoid tuberosity index (DTI) described by Spross et al.[40] DTI ≥ 1.4 or < 1.4 was considered as corresponding to normal or low bone mineral density (BMD) of the proximal humerus, respectively. The most reliable Hertel's criteria to predict AVN of the humeral head[14] were used, namely (a) postero-medial metaphyseal extension of less than 8 mm, (b) disruption of the medal hinge —related to medial or lateral displacement of the shaft of more than 2 mm with respect to the humeral head—, and (c) anatomical neck fracture. Quality of fracture reduction was categorized as anatomical, acceptable, and malreduced, assessed according to the Schnetzke criteria.[15]

Statistical analysis

Statistical analysis was conducted using Statistica 13.3.0 software package (StatSoft Inc, Tulsa, OK, USA). Descriptive analysis was performed to calculate frequency distributions, mean values, standard deviations (SDs), and 95% confidence intervals for each separate fixation technique. Independent-Samples *t*-test and Fischer's Exact Test were run to detect significant differences between the fixation techniques. Level of significance was set at 0.05 for all statistical tests.

Results

In total, 114 patients were surgically treated with simultaneous locked plating and intramedullary grafting (from January 2015 to November 2020). Sixteen patients passed away due to reasons unrelated to surgery. Three patients did not meet the inclusion criteria. Contact was established with 76 of the remaining 95 patients. Twenty-nine of them did not comply with the necessary visits in the hospital for a follow-up evaluation, mostly because of their advanced age and health concerns due to the coronavirus disease 2019 pandemic. As a result, 47 patients were retrospectively evaluated and appeared for final follow-up of a minimum of 12 months post-surgery. The majority of them were female (79%). Patients' age was 60.5 $\pm$ 13.7 years (mean value $\pm$ SD, range 33–81 years) for ORIF and 66.3 $\pm$ 11.7 years (range 34–84 years) for MIPO. The follow-up period among all patients was 28 $\pm$ 17.2 months (range 12–79 months), with 27.4 $\pm$ 16.2 months (range 12–79 months) for ORIF and 29.6 $\pm$ 17.6 months (range 12–72 months) for MIPO. Patient, fracture, and surgical technique characteristics for ORIF and MIPO are detailed in Table 1.

Functional outcomes

The functional outcomes were satisfactory in terms of CS^{abs} with 57.3 $\pm$ 21.2 points for ORIF and 52.4 $\pm$ 18.9 points for MIPO, good in terms of CS^{rel} with 73.0 $\pm$ 24.1 points for ORIF and 73.9 $\pm$ 23.4 points for MIPO, and good in terms of CS^{indiv} with 69.6 $\pm$ 24.8 points for ORIF and 64.0 $\pm$ 25.5 points for MIPO. There were no significant differences between ORIF and MIPO in terms of CS^{abs}, CS^{rel}, and CS^{indiv}, $p \geq 0.409$. DASH was 14.8 $\pm$ 12.5 points for ORIF and 18.7 $\pm$ 14.5 points for MIPO, with no significant difference between them, $p = 0.324$.

Radiological outcomes

With an intraoperative NSA of 136.4 $\pm$ 13.3° and an NSA of 128.6 $\pm$ 13.1° at the final follow-up , its decrease for ORIF was 7.8 $\pm$ 9.4°. For MIPO, with an intraoperative NSA of 126.7 $\pm$ 15.9° and an NSA of 118.5 $\pm$ 20.2° at the final follow-up, its decrease was 8.2 $\pm$ 15.6°. The decrease of HHH was 0.6 $\pm$ 5.5 mm for ORIF—with an intraoperative

Table 2. Categories, outcome measures, surgical techniques, and *p*-values from statistical comparisons.

Categories	Outcome measures	ORIF	MIPO	*p*-value
Functional outcomes	CS^{abs}	57.3 ± 21.2	52.4 ± 18.9	0.409
	CS^{rel}	73.0 ± 24.1	73.9 ± 23.4	0.897
	CS^{indiv}	69.6 ± 24.8	64.0 ± 25.5	0.428
	DASH	14.8 ± 12.5	18.7 ± 14.5	0.324
	ROM			
	Forward elevation (affected, °)	124.1 ± 39.1	112.5 ± 42.8	0.336
	Forward elevation (contralateral, °)	163.7 ± 12.3	165.6 ± 15.1	0.637
	Lateral elevation (affected, °)	116.7 ± 40.7	109 ± 39	0.512
	Lateral elevation (contralateral, °)	161.9 ± 13.1	163.8 ± 14.7	0.641
	External rotation (affected, °)	59.4 ± 28.1	49.2 ± 28.5	0.223
	External rotation (contralateral, °)	85.7 ± 7.1	78.6 ± 20.2	0.106
	Internal rotation (affected)	T12 (lateral thigh – T7)	T12 (lateral thigh – T7)	
	Internal rotation (contralateral)	T7 (lateral thigh – T7)	T7 (lateral thigh – T7)	
Radiological outcomes	Intraoperative NSA (°)	136.4 ± 13.3	126.7 ± 15.9	0.028
	Final follow-up NSA (°)	128.6 ± 13.1	118.5 ± 20.2	0.047
	Decrease of NSA (°)	7.8 ± 9.4	8.2 ± 15.6	0.922
	Intraoperative HHH (mm)	13.5 ± 3.3	14.7 ± 4.9	0.906
	Final follow-up HHH (mm)	12.9 ± 4.1	13.3 ± 5.8	0.812
	Decrease of HHH (mm)	0.6 ± 5.5	1.4 ± 2.6	0.380
Complications	AVN of humeral head	5 (20%)	8 (32%)	0.327
	Resorption of GT	7 (28%)	1 (4%)	0.051
	Secondary varus of < 110°	1 (4%)	5 (20%)	0.084
	Secondary screw penetration	7 (28%)	7 (28%)	1.000
	SAIt	2 (8%)	3 (12%)	0.653
	Arthritic changes of glenohumeral joint	3 (12%)	1 (4%)	0.611
	Nonunion	0 (0%)	0 (0%)	–
	Superficial or deep infection	0 (0%)	0 (0%)	–
Reoperations	Hardware removal	1 (4%)	4 (16%)	0.084
	Arthroplasty	0 (0%)	1 (4%)	

ORIF: open reduction and internal fixation; MIPO: minimally invasive plate osteosynthesis; CS^{abs}: Absolute Constant–Murley Score; CS^{rel}: Relative Constant–Murley Score; CS^{indiv}: Individual Relative Constant–Murley Score; DASH: Disabilities of the Arm, Shoulder and Hand Score; ROM: range of motion; NSA: neck-shaft angle; HHH: humeral head height; AVN: avascular necrosis; GT: greater tuberosity; SAI: subacromial impingement.

HHH of 13.5 ± 3.3 mm and an HHH of 12.9 ± 4.1 mm at the final-follow up. For MIPO, the decrease of HHH was 1.4 ± 2.6 mm—with an intraoperative HHH of 14.7 ± 4.9 mm and an HHH of 13.3 ± 5.8 mm at the final-follow up. No significant differences were detected between ORIF and MIPOb in terms of decrease of both NSA and HHH, $p \geq 0.380$.

Significant difference between ORIF and MIPO was detected for the duration of the surgical procedure—84.7 ± 38.1 min for MIPO versus 165.8 ± 77.6 min for ORIF, $p < 0.001$.

The main clinical outcomes and complications for ORIF and MIPO are summarized in Table 2.

Complications

There were 25 complications in 16 patients after ORIF and 25 complications in 11 patients treated with MIPO. AVN of the humeral head indicated 5 ORIF (20.0%) and 8 MIPO (32.0%) complications. Secondary varus displacement with an NSA decrease of more than 10° revealed 10 ORIF (40.0%) and 7 MIPO (28.0%) complications. One of these ORIF and 5 of the MIPO complications were related to a final NSA of less than 110°. Secondary screw penetration through the humeral head characterized 7 ORIF (28.0%) and 7 MIPO (28.0%) complications, and resulted from secondary varus displacement in 1 of these MIPO and 2 of the ORIF patients, with AVN of the humeral head in 6 of the MIPO and 5 of the ORIF cases. No primary screw penetrations were observed for either technique. Subacromial impingement (SAI) was diagnosed in 2 ORIF (8.0%) and 3 MIPO (12.0%) cases. In 4 of these 5 cases it developed because of displacement and proximalization of the greater tuberosity (GT), and in 1 of the cases with ORIF the reason was secondary varus displacement. For ORIF and MIPO, arthritic changes of the glenohumeral joint due to AVN of the humeral head occurred in 3 and 1 of these cases, respectively. In 7 cases after ORIF and 1 case after MIPO, resorption of the GT was diagnosed.

No nonunions, superficial and deep infections, or axillary nerve damage were observed for either technique. Secondary surgical procedures were performed in 6 patients. Five of the procedures necessitated hardware removal due to AVN and secondary screw penetration—in 1 ORIF and 4 MIPO patients. One MIPO patient underwent arthroplasty after developing AVN and secondary screw penetration. No significant differences were found between the two techniques in terms of complications and reoperation rate.

Discussion

The main finding of the present study is that MIPO using LP supplemented with IMG is associated with a significantly shorter operative time compared to ORIF. However, the functional and radiological outcomes, and complication rates were comparable for both surgical techniques.

ORIF via the conventional deltopectoral approach is the most commonly applied fixation technique for treatment of unstable PHFs.[7,38,41] The advantages of ORIF include excellent visibility of the anterior aspect of the proximal humerus, ease in applying the LP, valuable options for extension of the exposure distally and proximally, and reduced risk of neurovascular injuries.[7,41] On the other hand, the disadvantages of ORIF are related to the inevitable soft tissue stripping, significant risk of AVN—due to damage to the ascending branch of the anterior circumflex artery—, and the limited exposure of the lateral aspect of the proximal humerus.[41,42] The MIPO technique with the deltoid splitting approach requires less soft tissue stripping and has a lower risk of injury to the anterior circumflex humeral artery, resulting in a lower rate of AVN.[41–43] In addition, MIPO provides direct access to the lateral aspect of the proximal humerus, however, the procedure could be technically challenging, especially in the medial part of the proximal humerus, as the fragments need to be reduced indirectly.[41] Another disadvantage of this technique is the possible risk of axillary nerve damage.[7,41,43] Regardless of the used technique, the LP fixation of unstable PHFs is still associated with a high complication rate.[44]

The use of IMG for augmentation of the LP fixation was introduced by Gardner et al. in order to decrease the number of complications.[17] Biomechanical studies conclude that IMG increases stiffness and failure load of the bone-implant constructs, and limits fracture displacements,[18–22] while simultaneously allowing interfragmentary micromovements.[18] This additional rather elastic stabilization meets Lill's criteria for setting of an ideal device for fixation of PHFs.[45] Overall, the available clinical studies demonstrate good or even excellent functional results with a small percentage of complications when using IMG with LP for treatment of unstable PHFs.[23–26]

The available literature reports show that when using LP plus IMG, most authors apply ORIF for fixation for unstable PHFs[23–29,31–36] and only one author applies MIPO with the deltoid splitting approach in this regard.[30] To the best of our knowledge, the current study is the first one comparing ORIF and MIPO techniques in presence of LP fixation with IMG. In a prospective randomized controlled trial, Sohn et al.[41] compared the two fixation techniques using LP without IMG for treatment of unstable PHFs and found no significant differences between them in terms of functional and radiological outcomes, however, the MIPO technique was related to significantly shorter operation time than ORIF. Another prospective randomized study by Bhayana et al.[43], comparing these 2 surgical techniques, came to a similar conclusion. The results of the present study further support these findings that are relevant in case of IMG augmentation too. Although the functional

and radiological outcomes do not appear to differ significantly, a shorter surgery duration may be beneficial for patients who have serious comorbidities and/or multiple fractures due to trauma.[41] One disadvantage of the MIPO technique is believed to be the potential damage of the axillary nerve that invariably lies over the plate holes occupied with calcar screws.[43] However, LP fixation with IMG through MIPO has the additional benefit of providing robust cortical support through IMG by eliminating the need of calcar screws.[46] The expectation that fracture reduction with MIPO is technically demanding may be supported by our results, showing that anatomical reduction is more prevalent in case of ORIF. However, the latter did not seem to affect the final functional outcomes of both techniques in the current study.

The functional outcomes of the current investigation are comparable with previously reported data on LP fixation with IMG in terms of DASH,[23–26,29,33] CS^{indiv} and CS^{rel}.[23–26,29,31,32,36] scores. In addition, the change of HHH for both techniques is within the reported range from 0.30 to 2.14 mm[24,26–28,31,32] being below the critical level of 5 mm. In the literature, the critical change of NSA varies between 5° and 10°[28,30,47,48], and some authors report values between 2.60° and 3.25°[28,30–32,34,36] which are superior to our findings. However, although the change of NSA reflects the loss of reduction, this is not the most accurate criterion for varus deformation, as some patients with a change of more than 10° still have NSA within the physiological range of 120–150°. We support the conclusion of Shnetzke et al.[15] that NSA between 110° and 120° still represents an acceptable varus deformation, while values below 110° are not acceptable.

The rate of AVN in previous investigations on PHFs fixed with LP plus IMG varies from 0% to 10.6%,[17,23–29,31,32] which is less than the rates reported in the current study. Besides, the current secondary screw penetration through the humeral head was much higher when compared with previous reports (0–4%).[17,24,28,31] Another complication, identified in this study and not reported in previous work focusing on PHFs treated with LP plus IMG, was SAI and GT resorption. We were not able to extract the reason for the latter. One possible reason might have been the potential injury of the anterior circumflex vessels due to the deltopectoral approach used in 7 out of the 8 patients.[42] Another potential reason might have been the allograft itself, as Miyamura et al.[49] pointed out that fibular cortical strut may interfere with the revascularization, resulting in tuberosity resorption. In all 8 patients with GT resorption, a fresh-frozen fibular allograft was used. The complication was diagnosed on the final follow-up X-rays, and the shoulder function was seriously altered in only 2 of the patients.

Although the current study showed higher complication rate compared with previous reports, there were no significant differences between ORIF and MIPO in terms of functional and radiological outcomes, and complications rate.

The present study has some limitations. First, it was limited by its retrospective design, which could have introduced selection bias and potential for confounding. Second, the sample size was relatively small and futher work on a bigger cohort is therefore required to confirm these results. Third, the number of surgeons performing the procedure could have been a source of potential bias, influencing the validity of the study. However, all surgeons were from the same department, they all had more than 10 years of experience in the management of PHFs prior to the beginning of this study, and the surgical technique did not involve a long learning curve. Fourth, the follow-up duration was also relatively short. The minimum follow-up period was 12 months that may not have been sufficient to identify all negative clinical aspects after osteosynthesis of PHFs. However, the actual mean duration of the follow-up in this study was 28 months that is similar to that reported in the literature.

Conclusions

Locked plating with intramedullary graft augmentation of unstable proximal humerus fractures demonstrates similar functional and radiological outcomes, and similar complication rates when comparing open reduction and internal fixation with minimally invasive plate osteosynthesis. However, minimally invasive plate osteosynthesis is related to significantly shorter surgical time versus open reduction and internal fixation.

Authors' contributions

All authors contributed to the conception of this study. In addition: Lyubomir Rusimov, Asen Baltov, Dian Enchev, and Mihail Rashkov contributed to the study design; Lyubomir Rusimov and Mariya Hadzhinikolova performed the data collection; Lyubomir Rusimov, Boyko Gueorguiev, Krasimira Prodanova, Mariya Hadzhinikolova, and Vladimir Rusimov analyzed the data; Krasimira Prodanova run the statistical analysis. Lyubomir Rusimov wrote the first manuscript draft; Boyko Gueorguiev, Vladimir Rusimov, and Mihail Rashkov revised the manuscript. All authors discussed the results and contributed to the final manuscript version. All authors read and approved the final manuscript version.

Acknowledgments

The authors are grateful to their patients for the cooperation during the diagnostic and treatment process, especially during the time of pandemic.

Declaration of conflicting interests

The authors declared no potential conflicts of interest with respect to the research, authorship, and/or publication of this article.

Ethical approval

The study was conducted in accordance with the principles of the Declaration of Helsinki as well as national legal and regulatory requirements. It was retrospectively registered and approval was granted by the local Ethics Committee of University Multiprofile Hospital for Active Treatment and Emergency Medicine "N. I. Pirogov", Sofia, Bulgaria (No. EC–01/26.01.2023).

Funding

The authors received no financial support for the research, authorship, and/or publication of this article.

Informed consent

Informed consent has been obtained from all participants in the study, including their agreement for publication of the results.

ORCID iDs

Dian Enchev https://orcid.org/0009-0002-5699-7770
Boyko Gueorguiev https://orcid.org/0000-0001-9795-115X
Mariya Hadzhinikolova https://orcid.org/0000-0001-8317-2083
Lyubomir Rusimov https://orcid.org/0009-0000-6868-497X

References

1. Nordqvist A and Petersson CJ. Incidence and causes of shoulder girdle injuries in an urban population. *J Shoulder Elbow Surg* 1995; 4: 107–112.
2. Baron JA, Karagas M, Barrett J, et al. Basic epidemiology of fractures of the upper and lower limb among Americans over 65 years of age. *Epidemiology* 1996; 7: 612–618.
3. Palvanen M, Kannus P, Niemi S, et al. Update in the epidemiology of proximal humeral fractures. *Clin Orthop Relat Res* 2006; 442: 87–92.
4. Launonen AP, Lepola V, Saranko A, et al. Epidemiology of proximal humerus fractures. *Arch Osteoporos* 2015; 10: –5.
5. Neer CS. Four-segment classification of proximal humeral fractures: purpose and reliable use. *J Shoulder Elbow Surg* 2002; 11: 389–400.
6. Bahrs C, Stojicevic T, Blumenstock G, et al. Trends in epidemiology and patho-anatomical pattern of proximal humeral fractures. *Int Orthop* 2014; 38: 1697–1704.
7. Laux CJ, Grubhofer F, Werner CML, et al. Current concepts in locking plate fixation of proximal humerus fractures. *J Orthop Surg Res* 2017; 12: 137.
8. Sproul RC, Iyengar JJ, Devcic Z, et al. A systematic review of locking plate fixation of proximal humerus fractures. *Injury* 2011; 42: 408–413.
9. Thanasas C, Kontakis G, Angoules A, et al. Treatment of proximal humerus fractures with locking plates: A systematic review. *J Shoulder Elbow Surg* 2009; 18: 837–844.
10. Osterhoff G, Hoch A, Wanner GA, et al. Calcar comminution as prognostic factor of clinical outcome after locking plate fixation of proximal humeral fractures. *Injury* 2012; 43: 1651–1656.
11. Hertel R. Fractures of the proximal humerus in osteoporotic bone. *Osteoporos Int* 2005; 16: 65–72.
12. Capriccioso CE, Zuckerman JD and Egol KA. Initial varus displacement of proximal humerus fractures results in similar function but higher complication rates. *Injury* 2016; 47: 909–913.
13. Chandrappa MH, Hajibandeh S and Hajibandeh S. Postoperative outcomes of initial varus versus initial valgus proximal humerus fracture: A systematic review and meta-analysis. *J Clin Orthop Trauma* 2017; 8: 14–20.
14. Hertel R, Hempfing A, Stiehler M, et al. Predictors of humeral head ischemia after intracapsular fracture of the proximal humerus. *J Shoulder Elbow Surg* 2004; 13: 427–433.
15. Schnetzke M, Bockmeyer J, Porschke F, et al. Quality of reduction influences outcome after locked-plate fixation of proximal humeral type-C fractures. *J Bone Joint Surg Am* 2016; 98: 1777–1785.
16. Campochiaro G, Rebuzzi M, Baudi P, et al. Complex proximal humerus fractures: Hertel's criteria reliability to predict head necrosis. *Musculoskelet Surg* 2015; 99: 9–15.
17. Gardner MJ, Boraiah S, Helfet DL, et al. Indirect medial reduction and strut support of proximal humerus fractures using an endosteal implant. *J Orthop Trauma* 2008; 22: 195–200.
18. Mathison C, Chaudhary R, Beaupre L, et al. Biomechanical analysis of proximal humeral fixation using locking plate fixation with an intramedullary fibular allograft. *Clin Biomech* 2010; 25: 642–646.
19. Bae JH, Oh JK, Chon CS, et al. The biomechanical performance of locking plate fixation with intramedullary fibular strut graft augmentation in the treatment of unstable fractures of the proximal humerus. *J Bone Joint Surg Br* 2011; 93: 937–941.
20. Osterhoff G, Baumgartner D, Favre P, et al. Medial support by fibula bone graft in angular stable plate fixation of proximal humeral fractures: an in vitro study with synthetic bone. *J Shoulder Elbow Surg* 2011; 20: 740–746.
21. Chow RM, Begum F, Beaupre LA, et al. Proximal humeral fracture fixation: Locking plate construct ± intramedullary fibular allograft. *J Shoulder Elbow Surg* 2012; 21: 894–901.
22. Hsiao CK, Tsai YJ, Yen CY, et al. Intramedullary cortical bone strut improves the cyclic stability of osteoporotic proximal humeral fractures. *BMC Musculoskelet Disord* 2017; 18: 64.
23. Neviaser AS, Hettrich CM, Beamer BS, et al. Endosteal strut augment reduces complications associated with proximal humeral locking plates. *Clin Orthop Relat Res* 2011; 469: 3300–3306.
24. Matassi F, Angeloni R, Carulli C, et al. Locking plate and fibular allograft augmentation in unstable fractures of proximal humerus. *Injury* 2012; 43: 1939–1942.
25. Chen H, Ji X, Zhang Q, et al. Clinical outcomes of allograft with locking compression plates for elderly four-part proximal humerus fractures. *J Orthop Surg Res* 2015; 10: 114.
26. Hinds RM, Garner MR, Tran WH, et al. Geriatric proximal humeral fracture patients show similar clinical outcomes to non-geriatric patients after osteosynthesis with endosteal fibular strut allograft augmentation. *J Shoulder Elbow Surg* 2015; 24: 889–896.
27. Panchal K, Jeong JJ, Park SE, et al. Clinical and radiological outcomes of unstable proximal humeral fractures treated with a locking plate and fibular strut allograft. *Int Orthop* 2016; 40: 569–577.
28. Cha H, Park KB, Oh S, et al. Treatment of comminuted proximal humeral fractures using locking plate with strut allograft. *J Shoulder Elbow Surg* 2017; 26: 781–785.
29. Zhang L, Chen H, Yin P, et al. The augment of the stability in locking compression plate with intramedullary fibular

allograft for proximal humerus fractures in elderly people. *Biomed Res Int* 2018; 2018: 3130625.
30. Noh YM, Kim DR, Kim CH, et al. Minimally invasive percutaneous plate osteosynthesis via a deltoid splitting approach with strut allograft for the treatment of displaced 3- or 4-part proximal humeral fractures. *Clin Shoulder Elb* 2018; 21: 220–226.
31. Cui X, Chen H, Ma B, et al. Fibular strut allograft influences reduction and outcomes after locking plate fixation of comminuted proximal humeral fractures in elderly patients: a retrospective study. *BMC Musculoskelet Disord* 2019; 20: 1–8.
32. Lee SH, Han SS, Yoo BM, et al. Outcomes of locking plate fixation with fibular allograft augmentation for proximal humeral fractures in osteoporotic patients. Comparison with locking plate fixation alone. *Bone Jt J* 2019; 101: 260–265.
33. Davids S, Allen D, Desarno M, et al. Comparison of locked plating of varus displaced proximal humeral fractures with and without fibula allograft augmentation. *J Orthop Trauma* 2020; 34: 186–192.
34. Kim YK, Kang SW, Jung KH, et al. The potential of locking plate with intramedullary fibular allograft to manage proximal humeral fracture with an unstable medial column. *Arch Orthop Trauma Surg* 2022; 142: 91–97.
35. Myers DM, Triplet JJ, Warmoth PJ, et al. Improved outcomes using a fibular strut in proximal humerus fracture fixation. *Orthopedics* 2020; 43: 262–268.
36. Tuerxun M, Tuxun A, Zeng L, et al. Locking plate combined with endosteal fibular allograft augmentation for medial column comminuted proximal humeral fracture. *Orthopedics* 2020; 43: 367–372.
37. Fialka C, Oberleitner G, Stampfl P, et al. Modification of the Constant-Murley shoulder score—Introduction of the individual relative Constant score: individual shoulder assessment. *Injury* 2005; 36: 1159–1165.
38. Agudelo J, Schürmann M, Stahel P, et al. Analysis of efficacy and failure in proximal humerus fractures treated with locking plates. *J Orthop Trauma* 2007; 21: 676–681.
39. Gardner MJ, Weil Y, Barker JU, et al. The importance of medial support in locked plating of proximal humerus fractures. *J Orthop Trauma* 2007; 21: 185–191.
40. Spross C, Kaestle N, Benninger E, et al. Deltoid tuberosity index: a simple radiographic tool to assess local bone quality in proximal humerus fractures. *Clin Orthop Relat Res* 2015; 473: 3038–3045.
41. Sohn Hs, Sang Y, Lee J, et al. Clinical comparison between open plating and minimally invasive plate osteosynthesis for displaced proximal humeral fractures : a prospective randomized controlled trial. *Injury* 2017; 48: 1175–1182.
42. Patel S, Colaco HB, Elvey ME, et al. Post-traumatic osteonecrosis of the proximal humerus. *Injury* 2015; 46: 1878–1884.
43. Bhayana H, Kumar D, Sameer C, et al. Outcomes of plate osteosynthesis for displaced 3-part and 4-part proximal humerus fractures with deltopectoral vs. Deltoid split approach. *Eur J Trauma Emerg Surg* 2021; 48: 4559–4567.
44. Oldrini LM, Feltri P, Albanese J, et al. PHILOS Synthesis for proximal humerus fractures has high complications and reintervention rates: A systematic review and meta-analysis. *Life (Basel)* 2022; 12: 311.
45. Lill H, Hepp P, Korner J, et al. Proximal humeral fractures: how stiff should an implant be? A comparative mechanical study with new implants in human specimens. *Arch Orthop Trauma Surg* 2003; 123: 74–81.
46. Kim DS, Lee DH, Chun YM, et al. Which additional augmented fixation procedure decreases surgical failure after proximal humeral fracture with medial comminution: Fibular allograft or inferomedial screws? *J Shoulder Elbow Surg* 2018; 27: 1852–1858.
47. Lee C and Shin S. Prognostic factors for unstable proximal humeral fractures treated with locking-plate fixation. *J Shoulder Elbow Surg* 2009; 18: 83–88.
48. Bai L, Fu ZG, Wang TB, et al. Radiological evaluation of reduction loss in unstable proximal humeral fractures treated with locking plates. *Orthop Traumatol Surg Res* 2014; 100: 271–274.
49. Miyamura S, Lans J, Min KS, et al. Bone resorption of the greater tuberosity after open reduction and internal fixation of complex proximal humeral fractures : Fragment characteristics and intraoperative risk factors. *J Shoulder Elbow Surg* 2021; 30: 1–2.